

Role of FNAC in the Diagnosis of Cervical Lymphadenopathy

Deepshikha Dave¹, Arpita Nishal², R.N.Hathila³, Chintal Patel⁴

Abstract

Background: The incidence of lymphadenopathy appears to be increasing, especially among young adults all over the world. Frequent involvement of lymph node in regional and systemic diseases as well as their easy accessibility makes FNAC suitable tool for pathologists & clinicians. Inflammatory and immune reactions are the most frequent causes of lymph node enlargement and are self limiting in majority of cases. Lymphoid tissue undergoes reactive changes to a wide variety of antigenic stimuli. Tuberculosis, which is common in India, can be diagnosed by cytology of affected lymph nodes. Lymph nodes are also affected as a result of primary neoplasm of the node itself and from metastasis of malignant neoplasm from regional and distant organs. With the advent of FNAC, most of the inflammatory, reactive and neoplastic conditions can be diagnosed without biopsy. FNAC is a helpful tool for taking decision regarding excision of node, distinguishing benign from malignant mass and deciding type of malignancy. It has the advantage that it can be done safely, rapidly and cheaply with minimal trauma at an outpatient setup or at the bedside.

AIMs & Objectives: (1) To evaluate the role of FNAC in patients presenting with lymph node enlargement. (2) To find out the frequency of lymphadenopathy in different age groups. (3) To assess the distribution of various cytomorphological patterns of cervical lymphadenopathy; (4) To assess the age specific distribution of various cytomorphological patterns of cervical lymphadenopathy.

Materials & Methods: This study was carried out at Government Medical College and Hospital, Surat, on 386 clinically diagnosed cases of cervical lymphadenopathy over a period of one year from January 2015 to December 2015. Fine Needle aspiration Diagnosis was correlated with details of relevant clinical findings and investigations.

Results: Total 386 cases were studied, out of these 319 (82.64%) were found inflammatory and 67 (17.35%) were neoplastic. Tuberculosis was the most common disease found in 219 (56.73 %) patients followed by reactive nonspecific lymphadenitis in 100 (25.90 %) patients, Metastatic tumours in 60 (15.54%) patients & Lymphoma in 7 (1.81%) patients. Highest incidence of cervical lymphadenopathy was found in patients of 21 to 40 years age group.

Conclusion: Fine Needle aspiration Cytology (FNAC) is easy, simple, safe, reliable and non-invasive procedure for diagnosis of cervical lymphadenopathy.

Keywords: Cervical lymphadenopathy, FNAC, Tuberculous lymphadenitis, Reactive lymphadenitis

I. Introduction

Lymphadenopathy is one of the commonest clinical presentations of patients, attending the outdoor department. Cervical lymphadenopathy is usually defined as cervical nodal tissue measuring more than 1 cm in diameter. It could be due to infection, autoimmune disease or malignancy.[1]

Based on the duration, cervical lymphadenopathy is further classified into acute lymphadenopathy (2 weeks duration), sub acute lymphadenopathy (2-6 weeks duration), and chronic lymphadenopathy is considered in any lymphadenopathy that does not resolve by 6 weeks.[2]

Fine needle aspiration cytology is a cheap and accurate first line investigation in lymphadenopathy.[3] Because of early availability of results, simplicity, minimal trauma and complications, the aspiration cytology is now considered as a valuable diagnostic aid and it provides ease in following patients with known malignancy and identification of metastasis or recurrence.[4]

The diagnostic yield of FNAC can be improvised if it is accompanied by radiological guidance like ultrasonography and computed tomography scan. The outcome of FNAC can be improved by proper clinical assessment of lesion, careful procedure and adequate smear preparation. On-site evaluation can also lead to the appropriate triage for flow cytometry, microbiologic culture, and other ancillary studies [5]. The present study was carried out to know the overall prevalence of various diseases responsible for cervical lymphadenopathy.

II. Materials And Methods

This is a retrospective study carried out at the cytopathology section of Government medical College, Surat, India. Data concerning cervical lymph node FNAC was retrieved from the archives of one year (January 2015 to December 2015). A total of 400 patients with cervical lymphadenopathy were subjected to FNAC. Written informed consent was obtained from all patients. The detailed clinical findings, relevant laboratory and radiological findings were recorded before performing FNAC. FNAC was performed on the representative

cervical lymph node under strict aseptic precautions. The palpable cervical lymph node was fixed with one hand and a 22 gauge needle, attached to a 10 ml syringe was inserted into the lymphnode and aspirated with no suction in initial strokes then applying full suction. The tip of the needle was briskly moved up and down and sideways a few times till a spot of material showed in the stem of the needle. The negative pressure in the syringe was then released and the needle was withdrawn. The aspirated material was then blown on a clean glass slides using the same syringe. Smears were prepared on glass slides, few fixed in alcohol and few air dried, stained with Haematoxylin and Eosin and Leishman's stain. Necrotic aspirates were also submitted for Zeihl-Neelsen (ZN) staining for Acid Fast Bacilli (AFB). 14 Cases in which cytological material was inadequate or diagnosis was equivocal were excluded from the study. Hence a total 386 cases were available for analysis.

Based on cytopathological patterns observed, the cases were categorized into the following groups:

(1) Reactive hyperplasia: Smears were very cellular, showing a polymorphous population of lymphoid cells and histiocytes

(2) Tuberculous lymphadenitis: Epithelioid granulomas with or without caseous necrosis and giant cells. Smears showing only caseous material were also grouped under this category.

(3) Metastatic malignancy: Malignant cells arranged in clusters or discretely along with other lymphoid cells. Metastatic carcinoma was subdivided according to cytological features.

(4) Lymphomas: Cases with a mixed cell population and the characteristic Reed- Sternberg giant cell were categorised as Hodgkin's lymphoma. Non Hodgkin's lymphoma showed a monomorphous population of small lymphoid cells or lymphoblasts.

III. Results

In this study 400 patients were subjected to FNAC for cervical lymphadenopathy. Among these patients, in 10 cases, the aspirate was inadequate despite repeated endeavours and in 04 cases the opinion offered was equivocal. Hence these 14 cases were excluded from the study.

There were 213 males and 173 females in the study. The male: female ratio in this study was 1.23:1, with a slight male preponderance. The age of presentations from 6 months to 85 years with mean age in the middle of third decade. Maximum number of patients were in the 21-40 years age group (174 cases, 45.07%) followed by the age group 0-20 years (118 cases, 30.56%).

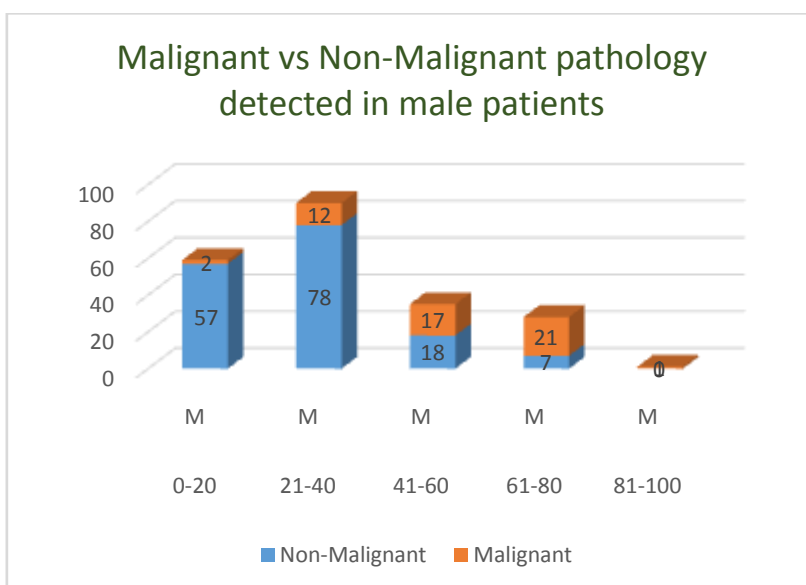
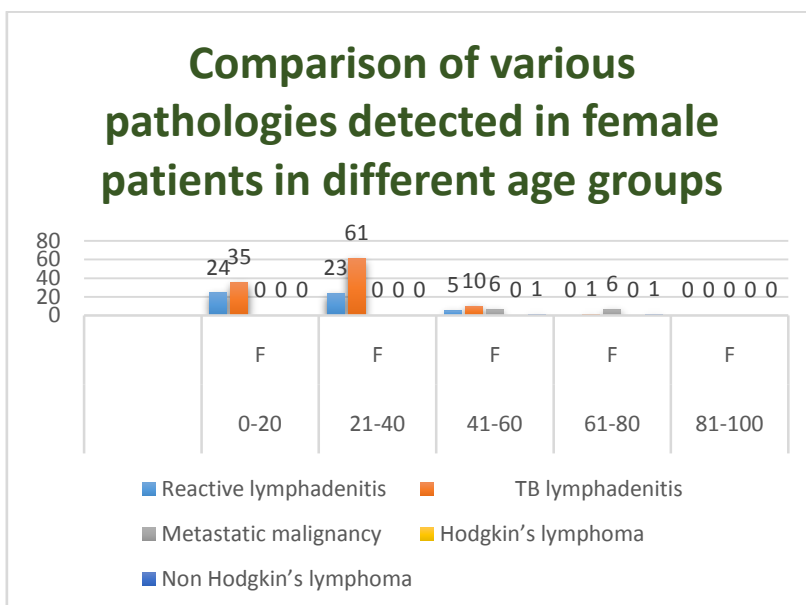
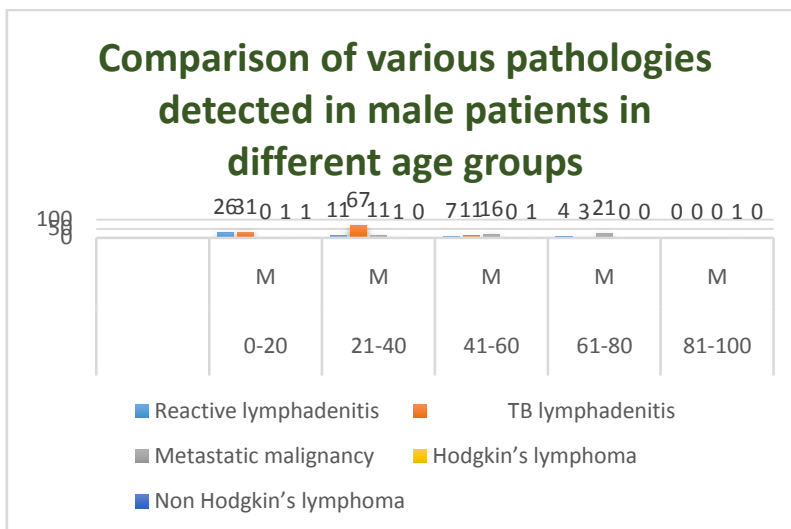
Tuberculous lymphadenitis accounted for a total of 219 cases (56.73%). This was the most common presentations of cervical lymphadenopathy in the current study. Reactive lymphoid hyperplasia was noted in 100 patients (25.90%). Among these patients 52 patients were in 0-20 years age group and 38 patients in 21-40 age group.

Metastatic malignancy was observed 60 cases (15.54%) with squamous cell carcinoma topping the incidence (30 cases, 50%). 3 Cases of Hodgkin's lymphoma & 4 cases of Non Hodgkin's lymphoma were diagnosed.

Table 1: summary of FNAC of cervical lymphadenopathy

Age (Years)	Sex	Reactive lymphadenitis	TB lymphadenitis	Metastatic malignancy	Hodgkin's lymphoma	Non Hodgkin's lymphoma
0-20	M	26	31	-	01	01
0-20	F	24	35	-	-	-
21-40	M	11	67	11 (8-SCC, 1-ADC, 2-PDC)	01	-
21-40	F	23	61	-	-	-
41-60	M	07	11	16 (10-SCC, 1-ADC, 5-PDC)	-	01
41-60	F	05	10	06 (4-SCC, 2-PDC)	-	01
61-80	M	04	03	21 (13-SCC, 1-ADC, 7-PDC)	-	-
61-80	F	-	01	06 (3-SCC, 3-PDC)	-	01
81-100	M	-	-	-	01	-
81-100	F	-	-	-	-	-
TOTAL		100 (25.90%)	219 (56.73%)	60 (15.54%)	03 (0.77%)	04 (1.03%)

SCC- Squamous cell carcinoma, ADC- Adenocarcinoma, PDC- Poorly differentiated carcinoma



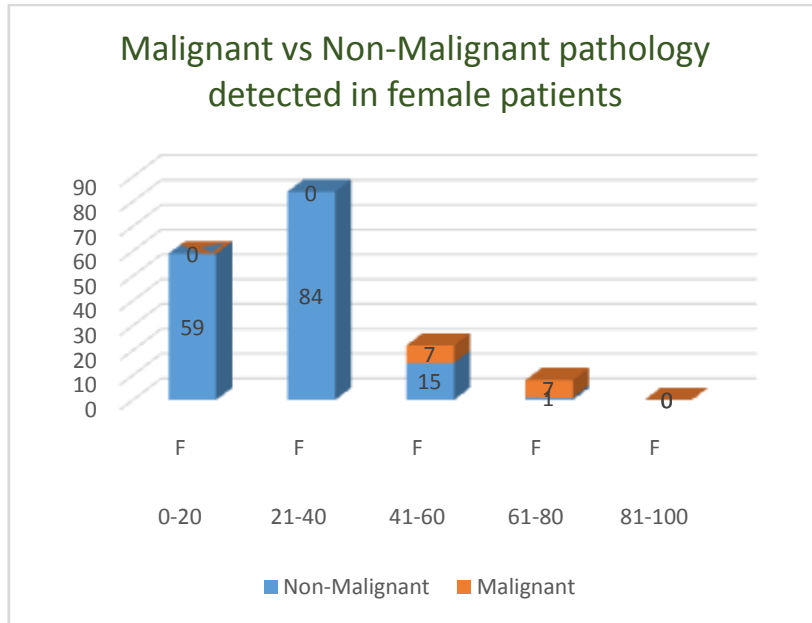
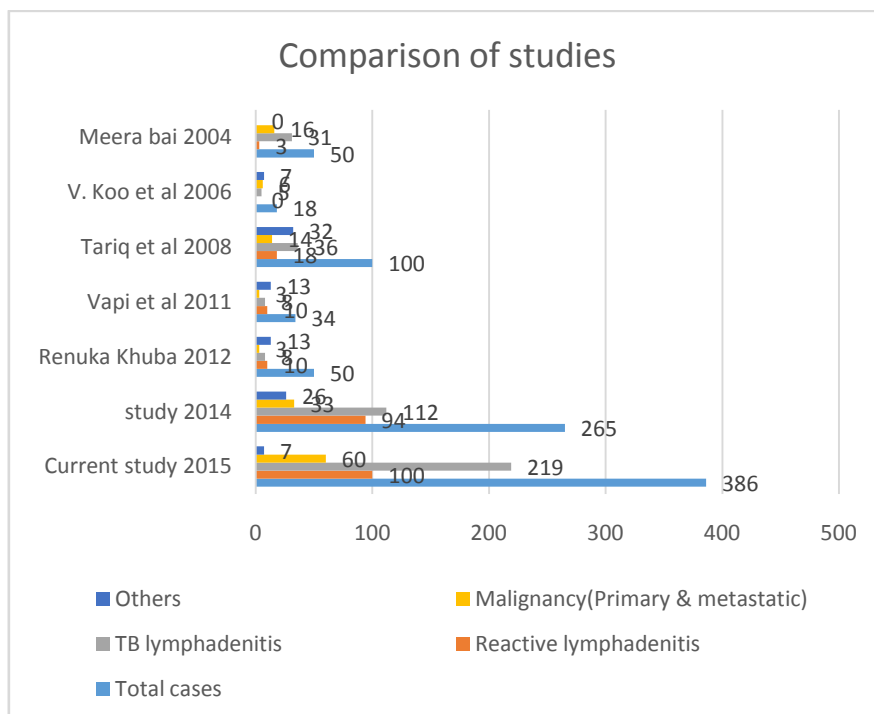


Table 2: Comparison of current study with other studies evaluating causes for cervical lymphadenopathy

Author	Total cases	Reactive lymphadenitis	TB lymphadenitis	Malignancy (Primary & metastatic)	Others
Current study 2015	386	100	219	60	07
study 2014	265	94	112	33	26
RenukaKhuba 2012	50	10	08	03	13
Vapi et al 2011	34	10	08	03	13
Tariq et al 2008	100	18	36	14	32
V. Koo et al 2006	18	00	05	06	07
Meerabai 2004	50	03	31	16	00

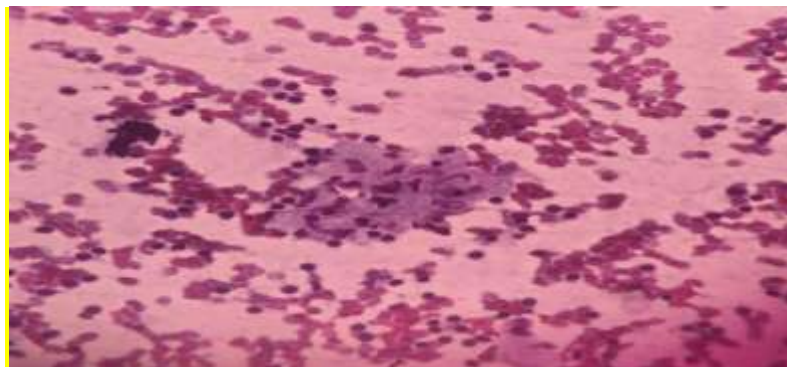


IV. Discussion

Cytology of lymph nodes has become a window for diagnosis of many diseases. Optimal material and experience, when combined, makes cytological diagnosis of equal significance as histopathology.[6]Localized or regional lymphadenopathy is defined as the enlargement of lymph nodes within contiguous anatomic regions. Viral, bacterial or mycobacterial infections, depending on the world region, are the most common causes of benign regional lymphadenopathy. The well-defined role of FNAC in the investigations of lymphadenopathy has previously been studied [7]. It plays a significant role in developing countries like India, as it is relatively a cheap procedure, simple to perform and practically almost has no complications. Many times, an aspirate may be the only tissue available for offering a diagnosis, as sometimes a surgical biopsy may not be possible for various reasons.

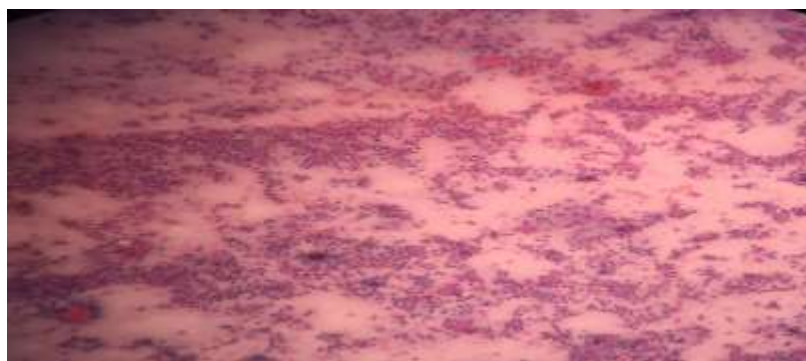
In the current study, 319 out of 386 cases (82.64%) were benign in nature whereas 67 cases (17.35%) had a malignant pathology. Among the benign causes of lymphadenopathy, the most common was tuberculosis accounting for 219 cases (56.73%) followed by reactive lymphadenitis (100 cases, 25.90%).

The high incidence of TB in the study may be due to the endemicity of the disease in India. This may be explained by the fact that in a developing country like ours, all cases of granulomatous lymphadenopathy were considered to be due to tuberculosis. Though the duration of protection of BCG vaccination is supposed to be 15-20 years, the high incidence of tuberculosis in patients less than 20 years of age is alarming. This corroborates with other studies that find a rising trend of extra pulmonary tuberculosis in BCG vaccinated children. Moreover the most common form of extra pulmonary tuberculosis is tuberculous lymph adenitis with cervical lymph nodes being the most commonly involved groups. In a study of 1936 cases of FNAC of cervical lymphadenopathy Rameshkumar found the most common benign lesion to be tuberculosis (54%) [9]. Bezabih et al found FNAC reliable in helping to avert more invasive surgical procedures undertaken in the diagnosis of tuberculous adenitis. They suggested adding ZeihlNeelsen stain for identification of acid fast bacilli as an adjunct to increase the diagnostic accuracy of tuberculous lymphadenitis [10]. In the study of Tariq et al in 2008 tuberculous lymphadenitis was found to be the most common pathology of cervical lymph node lesions [11].



AFB positivity was maximum in cases showing caseous necrosis with occasional epithelioid cells. The presence of acid fast bacilli in smears is directly proportional to the necrosis and inversely to the granulomas. Sometimes in absence of AFB positivity the diagnosis of 'highly suspicious of tuberculosis' was given in these lesions with strong clinical suspicion and correlation with clinical findings.

The second most common cause of cervical lymphadenopathy in the study was due to reactive hyperplasia. This was found to be common in the younger age groups i.e less than 40 years. Since infections from oral cavity, ears, nose and para nasal sinuses drain into these nodes, reactive lymphoid hyperplasia is a common finding[12]. Etiology is diverse and more often affects children rather than elderly.



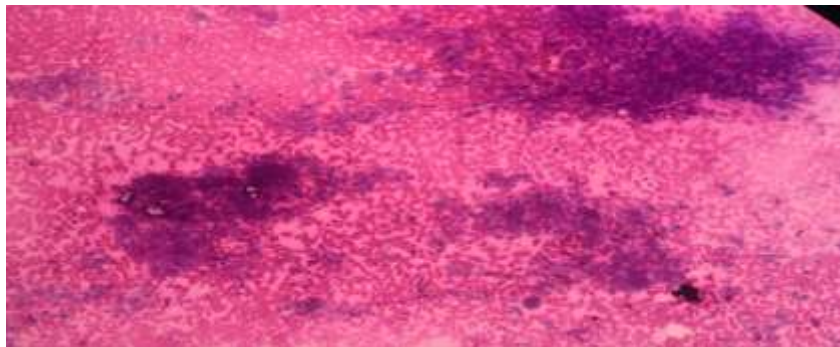
FNAC aided by ultrasound with its high sensitivity and specificity is a useful investigation to differentiate lymphoma from metastasis.

The incidence of reactive lymph node enlargement fall steadily the 6th decade onwards and that incidence of malignant lesions rises. Hence the pressing need for FNAC of neck nodes is significant in the elderly that can provide an early clue to the diagnosis.[13]

The study also documents higher incidence of malignancies particularly metastases in the higher age groups i.e 41-60 years and 61-80 years. FNAC has a documented higher sensitivity in the diagnostic workup of metastatic malignancies which may be due to the fact that metastatic carcinoma cells are usually abundant and their cytologic features are dissimilar to that of the cells of normal or hyperplastic lymph nodes[14,15].

In case of metastasis, squamous cell carcinoma was found in majority of cases (30 out of 60 cases, 50%). Hirachand et al also noted the commonest type of metastatic carcinoma to lymph nodes was of squamous cell variety [16]. Cervical lymph nodes, particularly high jugular and posterior cervical nodes, drain the head and neck and may harbour metastatic carcinomas originating in the nasopharynx, tonsillar fossa, tongue, floor of the mouth, thyroid, extrinsic larynx, facial skin and scalp. The findings of the study support the established fact that metastatic squamous cell carcinoma of the head and neck is frequent after the age of 40. [17]In cases of squamous cell carcinoma in an upper cervical lymph node, panendoscopy is indicated, including biopsy of all suspected areas and blind biopsies of the common primary sites- nasopharynx, tonsil, base of the tongue, supraglottic larynx and piriform sinus [18].

Figure 1: Cytology smear showing clusters of keratinizing squamous carcinoma indicating metastasis in the lymph node. (MGG X 400)



Carcinomas of nasopharynx and oropharynx are notorious for presenting with metastases in the cervical lymph nodes while the primary neoplasm unnoticeable [19].

FNAC is a useful prognostic tool in stage III cancers wherein metastasis to regional lymph nodes is usually found. It also aids in the diagnostic workup of a metastatic tumour of unknown origin. The suggested protocol for the managements of patients with cervical lymphadenopathy without an obvious primary site of origin starts with fine needle aspiration to establish a cytological diagnosis.

FNAC not only confirms the presence of metastatic disease but also helps in concluding the nature (origin) of primary tumour.

In recent years, FNAC of lymph nodes supplemented by ancillary studies has been increasingly accepted as an approach for primary diagnosis of reactive lymphoid lesions and lymphomas. [20,21].In our study only 7 primary lymphomas (3 Hodgkin's and 4 non-hodgkin's) were diagnosed on cervical node FNAC. The accuracy of cytological diagnosis is still limited in some forms of Non hodgkin's lymphoma, notably lymphomas with small cells, mainly marginal zone lymphoma, peripheral T cell lymphoma & T cell/ Histiocyte rich B cell lymphoma, nodular lymphocytes predominant hodgkin's lymphoma [17]; That's why, subtyping of hodgkin's & non hodgkin's lymphomas was not done in current study.

V. Conclusion

The present study highlights the usefulness of Fine needle aspiration cytology that fulfilled the primary aim to help the clinician in arriving at early diagnosis in cases presenting with cervical lymphadenopathy. A myriad of lesions causing cervical lymphadenopathy can be successfully identified on FNAC. In the current study, the most common causes were tuberculosis, reactive hyperplasia and metastatic malignancies particularly squamous cell carcinoma deposits. FNAC combined with clinical correlation can be used as a first line investigation in work up of lymph node lesions. Further management depending upon the causes can be suitably guided by this simple, cost effective procedure.

Founding : Nil. **Conflict of interest :** None

References

- [1]. MukulPatar, KusumBorsaikia, Biraj. K. Das, AnupamHazarika. A clinicopathological evaluation of cervical lymphadenopathy in children (0-14 Years) By fine needle aspiration cytology and histopathological examination - A hospital based study National journal of Otorhinolaryngology and Head and Neck surgery. 2014 (11):12-14
- [2]. Allhiser JN, Macknight TA, Shank JC. Lymphadenopathy in a family practice. *J Fam Pract*. 1981;12(1):27-32
- [3]. Steel BL, Schwartz MR, Ramzy I. Fine needle aspiration biopsy in the diagnosis of lymphadenopathy in 1,103 patients. Role, limitations and analysis of diagnostic pitfalls. *Acta Cytol*. 1995;39(1):76-81
- [4]. Ghartimagar D, Ghosh A, Ranabhat S, Shreshtha MK, Narasimhan R, Talwar OP. Utility of fine needle aspiration cytology in metastatic lymph nodes. *Journal of pathology of Nepal*. 2011; (2):92-95
- [5]. Saleh h, Masood S. Value of ancillary studies in fine-needle aspiration biopsy. *Diagn Cytopathol* 1995;13(4):310-5
- [6]. Koss LG. *Diagnostic Cytology and the Histopathological Basis*. 4th ed. Philadelphia: Lippincott Company; 1994. p.194-8.
- [7]. McAdams HP, Rosado-de- 1.A.G. Gonsal Diagnosis of tuberculosis. *Journal of Indian Medical association*. 2000;98(3):57-61
- [8]. Diagnosis of lymphadenopathies by FNAC: a prospective study
- [9]. Dr. Kandukuri Mahesh Kumar, Dr. Chinthakindi Sravan, Dr. Swarupa Ravuri, Dr. Divyagna
- [10]. Ramesh kumar K. Tuberculous lymphadenitis in children--role of fine needle aspiration cytology. *J Assoc Physicians India*. 1999;47(10):976-979
- [11]. Bezaib M, Mariam DW, Selasse Sg. Fine needle aspiration cytology of suspected tuberculous lymphadenitis. *Cytopathology*. 2002; 13(5):284-290
- [12]. Tariq ahmad, Mohammad Naeem, Siddique Ahmad, Ambreensamad. Fine needle Aspiration cytology and Neck swellings in the surgical outpatient. *J Ayub Med Coll Abbottabad* 2008;20(3):30-32
- [13]. Shakera N Baji, Vaishali Annand, Richa Sharma, Kunal S Deore, Mital Chokshi. Analysis of FNAC of cervical lymph nodes Experience over a two years period. *International Journal of Medical Science and Public Health*. 2014;3(5):607-609
- [14]. Gupta AK, Nayar M, Chandra M. Critical appraisal of fine needle aspiration Cytology in tuberculosis. *Acta Cytol* 1992;36:391-4.
- [15]. Frable WJ. Fine needle aspiration biopsy; a review. *Hum Pathol* 1983;14(1):9-28
- [16]. Volmor KE, Singh HK, Gong JZ. The advantages and limitations of the role of core needle and fine-needle aspiration biopsy of lymph nodes in the modern era. Hodgkin and Nonhodgkin lymphomas and metastatic disease.
- [17]. Hirachand S, Lakhey M, Akhter J, Thapa B. Evaluation of fine needle aspiration cytology of lymph nodes in Kathmandu Medical College, Teaching hospital. *Kathmandu university Medical journal*. 2009;7(26):139-142
- [18]. Orell- 5th edition
- [19]. Vokes EE, Weichselbaum RR, Lippman SM. *Head and Neck cancer*. *N Engl J Med* 1993; 328(3):185-194
- [20]. Loke YW. Lymphoepitheliomas of the cervical lymph nodes. *Br J Cancer* 1965;19(3):482-485
- [21]. Mathiot C, Decaudin D, Klijabienko J, et al. Fine-needle aspiration cytology combined with flow cytometry immunophenotyping is a rapid and accurate approach for the evaluation of suspicious superficial lymphoid lesions. *Diagn Cytopathol* 2006; 34(7):472-478.
- [22]. Venkatraman L, Catherwood MA, Patterson a, et al. Role of polymerase chain reaction and immunocytochemistry in the cytological assessment of lymphoid proliferations. *J Clin Pathol* 2006;59(11):1160-1165